

The Synergistic, amplifying use of Micronized Flavanoid Fraction, proprietary ceramide emulsion, and dermal microdeformation fuzzy wale compression under inelastic compression for the management of Venous Leg Ulcers

■ Matthew M. Melin, MD, FACS, RPVI, FACCWS; Jennifer Reinders, WOCN; Angie Wubben, WOCN; Katie Cecconi, PA ■ Wound Healing Institute, M Health Fairview, Edina, MN

SYNOPSIS

Venous Leg Ulcers (VLU), based upon revision of the Starling principle in 2010 (1), are now recognized to be associated with significant dermal and deep lymphatic dysfunction in addition to Chronic Venous Insufficiency (CVI), also known as phlebolymphe-
dema. Dermatitis is a near consistent, aggravating component of VLUs and contribute to wound non-closure and early recidivism. The standard of care VLU treatment has typically focused on venous procedures/ablation in an attempt to eliminate the superficial venous hypertension component of CVI and graded compression stocking utilization with little attention to the dermatitis component (2). Our Wound Clinic practice has begun to actively manage the dermatitis component of VLUs through consistent use of

- 1) oral Micronized Purified Flavanoid Fraction (3, 4)
- 2) proprietary emulsion composed of a 3:1:1 ratio of Ceramide: Conjugated linoleic acid: cholesterol (5,6)
- 3) fuzzy wale compression garment (7, 8) applied under inelastic compression to achieve minimum 20-30mmHg gradient compression.

OBJECTIVE

Assess use of simultaneous treatment methods for accelerated wound healing and dermatitis improvement

CONCLUSIONS

The dermal lymphatic component of VLUs and CVI remains a significantly underrecognized, under-appreciated and undermanaged component of treatment, resulting in slow wound closure times and unacceptable high recidivism rates. The synergistic, amplifying, consistent application of the 4 components of oral MPFF (diosmiplex 630mg), proprietary 3:1:1 ceramide dominant emulsion, fuzzy wale dermal microdeformation under inelastic compression resulted in accelerated wound closure outcomes for the 3 patient series described. The impact of oral MPFF (diosmiplex 630mg) of increased lymphatic and venous tone with decreased ICAM and VCAM, combined with direct dermal lymphatic stimulation, potentially resulting in increased lymphangion contractility, significantly reduces interstitial edema. A larger, randomized controlled clinical trial is indicated

METHODS

A case series of three patients with CVI, Phlebolymphe-
dema, VLU and dermatitis

- Debridement, biopsies as indicated, Ankle Brachial Indices (ABI) and venous insufficiency ultrasounds were performed
- Patients were initiated on oral MPFF (diosmiplex 630mg (Vasculera)), proprietary 3:1:1 ceramide dominant emulsion
- (EpiCeram), fuzzy wale dermal microdeformation compression under inelastic compression
- VLU specific dressing included HOCL washes and an antibacterial foam
- Adjunctive micronutrient therapy consisting of Vitamin D, C, B12 and folate are advised
- MTHFR status is evaluate, B12 and Folate are utilized if hetero- or homozygous to improve endothelial functionality

Medical writing assistance for this poster was provided by Primus Pharmaceuticals:
M. Mark Melin MD is a sponsored educational presenter for Primus Pharmaceuticals

RESULTS

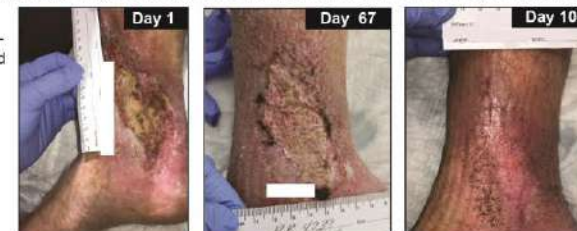Case #1

**67 year old male, CVI, phlebolymphe-
dema, complicated by work related chemical burn. Non diabetic, no tobacco use. ABIs normal, no PAD.**

■ Underwent radiofrequency ablation of incompetent R GSV 2 months prior to Wound Clinic consult, no improvement of wound size or pain. Post procedure use of standard 30-40mmHg graded static compression stocking, foam dressing to wound.

■ Multiple courses of antibiotic therapy.

■ **Day 1** Clinic consult Photo. Initiation MPFF (diosmiplex 630mg), proprietary 3:1:1 ceramide dominant emulsion, fuzzy wale dermal compression under inelastic compression, HOCL wound washes



■ Surgical Debridement day 2 and 67 (application cadaver skin)

■ Note longitudinal dermal microdeformation from fuzzy wale

■ **Day 104**, closed VLU, Pain markedly improved, Dermatitis improved. Continued daily ceramide, MPFF (diosmiplex 630mg), graded compression

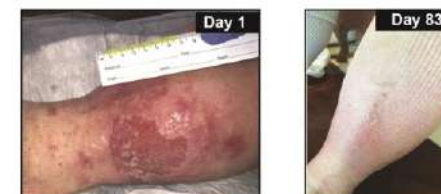Case #2

**83 year old female, CVI, phlebolymphe-
dema, obesity, adult onset diabetes, no PAD. No h/o DVT, PE.**

■ Chronic spinal stenosis, back pain, difficulty using compression stockings, chronic leg pain

■ Multiple episodes cellulitis, hospitalization for erysipelas left leg.

■ **Day 1** initiated MPFF (diosmiplex 630mg), proprietary 3:1:1 ceramide emulsion, fuzzy wale compression with inelastic compression (applied by husband)



Day 83

- Telehealth visit
- Wound closed, improved dermatitis

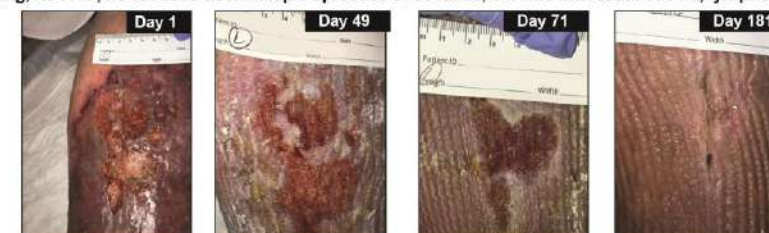
Case #3

45 year old male, obesity, AODM, prior left GSV stripping, no PAD, no tobacco use. Multiple episodes of cellulitis, chronic interstitial edema, lymphoedema.

■ **Day 1** initiation MPFF (diosmiplex 630mg), proprietary 3:1:1 ceramide dominant emulsion, fuzzy wale dermal compression under inelastic compression (intermittent 2 layer compression with nurse clinic changes), HOCL wash.

■ Serial clinic debridement of biofilm

■ Resolution of pain



REFERENCES

1. Levick JR, Michel CC. Microvascular fluid exchange and the revised Starling Principle. Cardiovascular Research 2010;87:198-210. 2. O'Donnell TF, Passman MA, et al. Management of venous leg ulcers: Clinical practice guidelines of the Society for Vascular Surgery and the American Venous Forum. J Vasc Surg 2014;60:3S-59S. 3. Raffetto JD, Eberhardt RT, Dean SM, et al. Pharmacologic treatment to improve venous leg ulcer healing. J Vasc Surg: Venous and Lym Dis 2016;4:371-4. 4. Ulloa JH. Micronized purified flavanoid fraction (MPFF) for patients suffering from chronic venous disease: a review of new evidence. Adv Ther 2019 doi.org/10.1007/s12325-019-0884-4. p. 1-6. 5. Choi MJ, Maibach HI. Role of ceramides in barrier function of healthy and diseased skin. American Journal of Clinical Dermatology 2005;6:215-223. 6. Sugerman JL, Parish LC. Efficacy of a lipid-based barrier repair formulation in moderate-to-severe pediatric atopic dermatitis. Journal of Drugs in Dermatology 2009;8(12):1106-1111. 7. Ehmann S, Walker KJ, Bailey CM, et al. Experimental simulation study to assess pressure distribution of different applications applied over an innovative primary wound dressing. Wounds 2020 Epub August 17; 1-11.
8. Wiegand C, White R. Microdeformation in wound healing. Wound Rep Reg 2013;21:793-799.