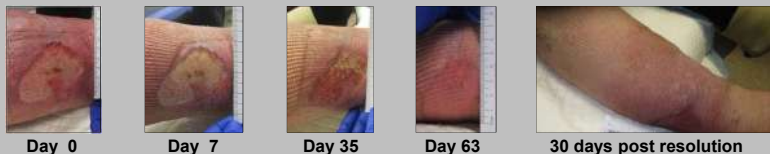


# Novel Use of Tubular Dressing for Lower Leg Wound Treatment – A Case Series

Denise Gilmore BSN, RN, CWON, CFCN & Kristina Fawcett MSN, NP-C, CWS



## Case #1 Promotion of Epithelial Growth

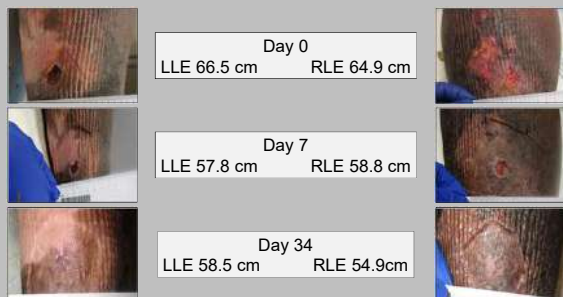


Day 0 Day 7 Day 35 Day 63 30 days post resolution

69 y/o male obese patient with venous insufficiency s/p venous ablation with history of recently resolved venous leg ulcer for 1 month. Ulcer recurred rapidly despite 30-40mmHg compression and daily use of intermittent pneumatic compression device. Prior successful treatment was slow for improvement. Patient transitioned into collagenase ointment with low profile dressing, TDS, absorptive dressing, Kerlix and Velcro compression system with daily change. Note desired impressions in wound bed and islands of epithelial growth

## Case #2 Promotion of Epithelial Growth and Edema Reduction

72 y/o male obese patient with Phlebolympheidema, and history of recurring venous leg ulcers. Rapid onset of wounds, precipitated by blistering from volume overload and ultimate ulceration of skin. Velcro compression garment and intermittent pneumatic compression device previously in use. Updated wound treatment consisted of gentian violet and methylene blue foam transfer dressing, TDS, and 3-layer compression wrap with weekly change.



Day 0  
LLE 66.5 cm RLE 64.9 cm

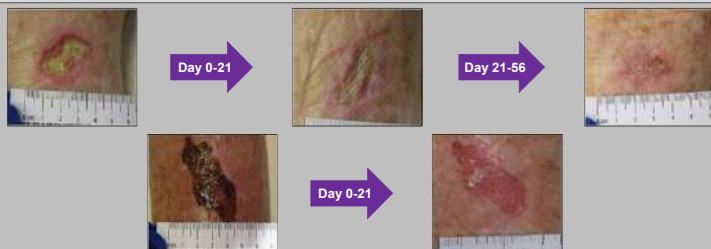Day 7  
LLE 57.8 cm RLE 58.8 cm

Day 34  
LLE 58.5 cm RLE 54.9cm

On Day 7, no additional clean TDS was available. Patient placed into standard 3-layer wrap. On day 14, he sustained a significant return of fluid volume to his legs, both limbs measured at 60 cm

## Case #3 Pain Reduction = Better Patient Compliance

80 y/o female with history of non-healing surgical site of left lower leg, basal cell carcinoma s/p MOHS excision, 2 months prior to presentation. Adjacent left lower leg was trauma from adhesive present for 1 month. Moist wound healing in progress however pain at wound sites was reason for consultation. Presented with moderate edema no vascular disease. Day 0 pain 9/10 on her surgical wound. Topical moist dressing, with low profile nonadherent dressing, with TDS, and absorptive dressing. Day 21 pain 6/10 with improved edema management. At time of d/c continued with TDS as edema management solution



Day 0-21

Day 21-56

Day 0-21

## ABSTRACT

In a community wound care clinic, introduction of a novel use of a tubular dressing securement system (TDS) influenced healing times on five patients who experienced venous, arterial, mixed, and lymphatic comorbidities with lower extremity wounds. Following standard of care for treatment of lower leg wounds, patients continued to have recalcitrant wound findings with wound age as little as 30 days and as long as 3 years. Desjardins et al. (2018) study on pressure mapping with use of Fuzzy Wale Compression, also known as TDS, demonstrated evidence of “alternating compression profile” noting that in lower areas of pressure venous and lymphatic vessels can remain open to allow for better reduction of edema. Clinic patients had an initial vascular evaluation, lower extremity and wound assessment, with physical examination. Patients received primary wound dressing application based on wound presentation and TDS was donned as the secondary dressing to allow for intimate contact with skin as per manufacturer recommendations. Patients followed up weekly and were re-evaluated. With the introduction of a TDS, healing times and edema measurements were greatly reduced, in addition to improved patient compliance with their compression management system. After implementation of TDS, wound healing times varied from 2 weeks to 3 months, in conjunction with a wound care dressing. Here are the presented case studies for five patients that were observed to have improvement in skin, reduction of edema, and improved wound healing times. In conclusion, the novel TDS is a dressing with many attributes displaying positive outcomes in wound healing for patients.

## Further Research Proposed

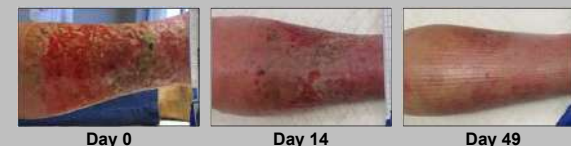
1. Could the alternating compression profile of the TDS work on the lymphatic system to allow for additional edema reduction similar to kinesio tape?
2. Should the lymphatic system be assessed during initial work up same as the venous and arterial systems?

## REFERENCES

Desjardins, J. D., Walker, K., Holter, A. M., Bailey, C., & Ehmann, S. (2018). An in-vitro pressure mapping evaluation of fuzzy wale compression with multi-layer compression. Symposium for Advanced Wound Care, Spring 2018. Retrieved from <https://compressiondynamics.com/wp-content/uploads/2018/05/PosterAnInVitro-Pressure-Mapping-Evaluation-of-Fuzzy-Wale-Compression-with-MultiLayered-Compression.pdf>  
Lymphatic diagram. (2016). Retrieved from <https://socratic.org/questions/what-is-the-role-of-lymphatic-system-in-the-absorption-of-fats>

Contact Information:  
Denise Gilmore – denise.cwocn@gmail.com  
Kristina Fawcett – KISSIEK24@aol.com

## Case #4 Limited Options

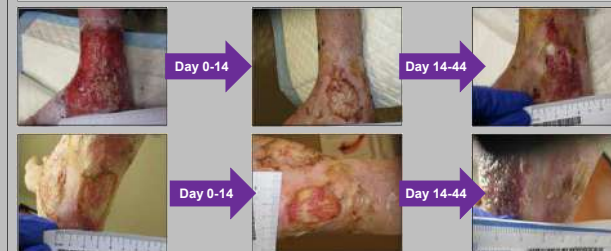

Day 0 Day 14 Day 49

84 year old female patient, former smoker, cardiovascular/valvular disease, peripheral arterial and venous disease. RLE wound open for 9 months, failed multiple wound care therapies and was advised hospice. She sought second opinion at our wound center. Arterial Duplex RLE demonstrated monophasic flow throughout leg with exception of occluded PTA and ATA; TBI 0.0. Initiated silver active fluid management dressing, TBS, absorptive dressing. Complete resolution within 8 weeks. Continues using TDS as a compression therapy to support lymphatics, remains healed 3 months later.

## Case #5 Dermatitis Reduction

79 y/o female patient with history of traumatic injury to her RLE with fixed ankle. Known peripheral arterial disease, TBI 0.0 with venous insufficiency. Wound present > 1 year. Topical dressings consisted of absorptive foams, alginates, fibers. Presentation: Severe stasis dermatitis with full thickness ulceration to medial ankle and Achilles. At day 0 initiated silver active fluid management dressing, TDS, and absorptive dressing.



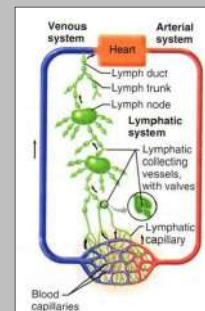
Day 0-14

Day 14-44

Day 0-14

Day 14-44

## Lymphatic Diagram



Six months post wound resolution with continued use of TDS for compression management

