Limb Ischemia is an Economic Contraindication to NPWT

3rd party payers will not reimburse for NPWT in ischemic limbs, a policy that can be worked around

Problems

- Diabetic, on hemodialysis, smoker
- Ischemic R leg aorto-iliac-femoral arterial occlusive disease. Angioplasty was rescheduled 3 x over 4 months due to 4 ICU visits for sepsis.
- 3rd party won't pay for NPWT Rx on ischemic limb

Rx Day #0. Debridement included necrotic fascia and black necrotic perineal muscle.

Treatment

- Wound enlarged via multiple debridement, in spite of best efforts over 105 days
- NPWT device was provided to the patient at no charge by Devon Medical- compassionate care use

Rx Day #158. ExtriCare NPWT Rx Day #33. Patient's wife changing ExtriCare dressing in clinic our as she did twice a week at home.

ExtriCare Rx Day #115. The collagen dressing adherent to the wound below the ExtriCare® dressing is Endoform, an ovine stomach collagen dressing™ which the patient purchased from Amazon online.

Rx Day #150. ExtriCare NPWT Day #45. Observe the healthy granulation tissue with stable epithelial cells evident along the wound edges. Endoform™ dermal template is an inexpensive ovine stomach collagen dressing that delivers growth factors to the wound while NPWT is utilized.

Outcome

- Providers "worked around" restrictive 3rd party payer regulation that restrict NPWT when ischemia is present
- Compassionate use NPWT salvages profoundly ischemic R lower extremity

Rx day #355. Minor skin breakdown has reoccurred. NPWT has salvaged limb for a year of independent living at home.

Background

Negative pressure wound therapy (NPWT) introduced in 1995, like cardio-pulmonary bypass machines enabled the first aortic valve replacement in 1967, has improved the lives of millions of patients with chronic wounds.1 None would argue that 3rd party providers must have written policies to regulate who receives what type of cardiac valve replacement. Patients with ischemic limbs who need NPWT face rigid regulatory hurdles from 3rd party payers creating a challenge for wound care providers.2,3

Methods

Two patients with profound ischemia, no Doppler signals were present in ipsilateral foot, with chronic limb threatening ischemic wounds were treated with NPWT. We worked around the policy of Nebraska Medicare and Iowa Medicaid to not pay for NPWT in ischemic limbs, by asking manufacturers to donate NPWT devices for compassionate care. Photographs document complete healing of all wound, angiogram results, and treatment details.

Results

NPWT healed all limb threating wounds in spite ankle brachial indices (ABI) of zero.

Conclusion

Third party payer policies restrict payment for NPWT in ischemic limbs in patients with non-correctable end stage arterial ischemia. For now, to salvage ischemic limbs, wound care providers must work around flawed payer policy.

References

1. In Memoriam John W. Kirklin 1917–2004, Denton A. Cooley, MD, Texas Heart International Journal 2004; 31(B) 113.

2. Evidence-based recommendations for the use of negative pressure wound therapy in chronic wounds: steps towards an international consensus, Vig S1, Dowsett C, Berg L, J Tissue Viability. 2011 Dec;20 Suppl 1:S1-18. J Tissue Viability. 2011 Dec; 20 Suppl 1:S1–18.

3. Kasai Y1, Nemoto H, Kimura N, Ito Y, Suniya N, . Application of low-pressure negative pressure wound therapy to ischaemic wounds. J Plast Reconstr Aesthet Surg. 2012 Mar;65(3):395-8.

*ExtriCare NPWT System, Devon Medical Inc., King of Prussia, PA
**Endoform Dermal Template, Hollister Wound Care Inc., Libertyville, IL
***EdemaWear®, *EdemaWear®LITE™*, Compression Dynamics LLC, Omaha, NE
****Kalypto NPWT System, Kalypto Medical Inc., acquired by Smith Nephew May 2012
*****Apligraf Bioengineered Skin Substitute, Apligraf® (Organogenesis, Canton, MA

Bob DeYoung, RN
Alegent Creighton Mercy Wound Care Center, Omaha, NE

Martin J. Winkler, MD, FACS
Alegent Creighton Mercy Wound Care Center, Omaha, NE

Alegent Health

Creighton University Medical Center

Problems

- Ischemic R foot ulcers
- Profound non-operable arterial ischemia
- L BKA
- Vasculopath, 3 packs/day smoker

Rx Day #0. Ischemic full thickness R foot ulcers. Comorbidities: multiple level arterial occlusive disease, R foot paralysis due to motor vehicle spinal injury, ischemic cardiomyopathy with 22% cardiac ejection fraction, chronic severe pain with narcotic habituation, smokes 3 packs cigarettes which in Mayo Clinic parlance means she is a vasculopath, on nasal O2 for obstructive pulmonary disease, sleeps sitting up with significant R foot edema.

Rx Day #0. Nine weeks after patient went home from rehab for left BKA, she presents with a new R foot ischemic ulcer, under a Rookie Boot.

Treatment

- Third party payer refused NPWT Rx because of arterial ischemia. Providers worked around this flawed policy.
- Compassionate use NPWT system was donated by Kalypto Medical Inc.
- Split-thickness skin graft in wound clinic
- Bioengineered skin substitute
- 22.5 KHz ultrasound debridement with hypochlorous acid irrigation

NPWT Day #30. Iowa Medicaid refused to pay for NPWT because of profound non- reconstructible ischemia. Seen here is Kalypto NPWT** System, Kalypto Medical Inc., acquired by Smith Nephew in May 2012. Kalypto donated a NPWT system for use on the full thickness R ankle ulcer. Size small fuzzy wale compression stockinet*** is used to stabilize the compression dressing and to decrease foot edema.

NPWT Rx Day #45. Observe 3 painful ischemic ulcers in this insensate paralyzed foot. Limb edema and moisture associated dermatitis were problems during NPWT. A decision was made to control pedal edema with fuzzy wale elastic compression stockinet*** (seen in second photo). Swelling explained in part because patient sleeps sitting up.

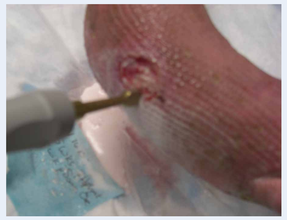

Rx Day #–45. Ultrasound debridement weekly for 5 weeks was well tolerated in face of considerable wound pain. Patient refused all mechanical debridement until intermittent low powered ultrasound frequency, 22.5 KHz, powered debridement was available. Hypochlorous acid (HOCl) was used to irrigate the ultrasound hand piece and at each wound debridement.

Outcome

- Ischemic wounds healed without scar day #150

RX Day –#90. Observe interval healing of the R ankle wound. Modalities to this point include: HOCl solution, Kalypto NPWT ****, System, Apligraf Bioengineered Skin Substitute***** and EdemaWear ***

Rx Day –#120. Observe that slow interval healing of the full thickness R ischemic ankle wound with minimal scarring of the skin.

Rx Day #–150. Observe interval healing of the R ankle wound with minimal scarring of the skin. Patient holds that healing was a miracle enabled by the Crucifix seen in photo, which has the Lord's Prayer etched on the round crystal at center. On final day in clinic, the prayer disappeared.

Wound care givers hold that miraculous or not healing without scarring is one clinical sign of regenerative healing. The key principal of regenerative healing is that wounds regenerate skin coverage from bone marrow derived precursors, in this case, Circulating Epithelial Precursors (CEPs).

Ultrasound debridement, NPWT, split-thickness skin grafts and bioengineered skin substitute,**** and control of swelling with Fuzzy Wale elastic compression stockinet,*** all contributed to the miraculous, say regenerative, healing and salvage of this profoundly ischemic leg.