Hemodialysis Access Wound Complications Respond to Fuzzy Wales Elastic Compression Therapy:

Control of venous hypertension in subcutaneous fat probable mechanism

Problem

- Infected surgical wound
- Dehiscence of surgical incision
- Exposed infected L brachial artery to L cephalic vein anastomosis (could threaten limb)
- End stage renal disease
- Diabetes

Therapy

- Surgical debridement of dehiscence
- Loose reclosure of wound skin with negative pressure wound foam application
- Fuzzy wale elastic compression stockinet* to control extensive post fistula edema

Outcome

- Dehiscence heals with NPWT + fuzzy wale elastic compression stockinet*
- Preservation of functioning dialysis graft
- Edema abates

Solution/Conclusion

- Fuzzy wale elastic compression stockinet* controls the massive edema that follow surgical creation of arterial venous fistula
- Fuzzy wale compression stockinet appears to improve healing of surgical incision after hemodialysis access procedures

Photo shows L arm after foam based negative pressure wound therapy, NPWT, is used over the surgical incision wound. Fuzzy wale elastic compression stockinet* therapy is used to control extensive L arm edema.

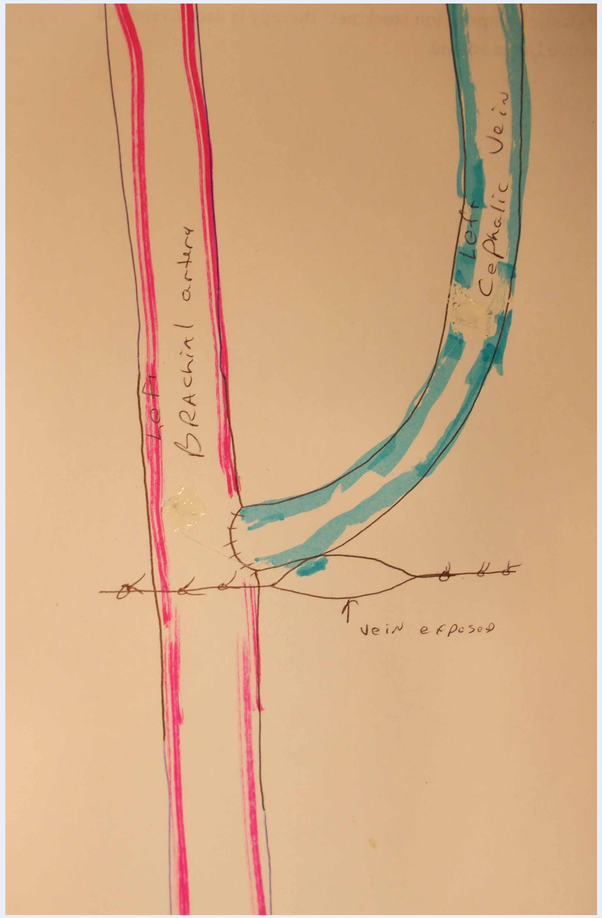

Surgeon's drawing after second trip to OR illustrates the open wound above a left brachiac artery to left cephalic vein hemodialysis fistula follow a wound dehiscence in skin stretched tight with massive edema of the subcutaneous fat. The surgical incision has been fell apart, exposing a vascular suture line to the outside elements, the second surgical procedure included:
1) Lavage and debridement of subcutaneous and wound exudate fat in the exposed wound
2) Loose reclosure of the wound to cover the artery / vein suture
3) Placement of foam for negative pressure wound therapy
4) placement of fuzzy wale elastic compression

Problem

Annually 350,000 persons require hemodialysis for ESRD in the United States.1 Surgical incision complications following arterial venous anastomosis are high, 5 to 20 percent, because venous hypertension and massive edema results when arterial blood is redirected into the venous system. Edema in the subcutaneous fat increases tension on suture the line, lymphorhea, and infection. Arterial suture line bleeding due to infection in the subcutaneous tissue can be limb threatening and often leads to ligation of the access.2 Kozeny reported a novel fuzzy wale elastic textile that effectively moves water out of the subcutaneous fat in 2007.3 We have extensive experience with fuzzy wale elastic compression to control edema after hemodialysis arterial venous fistula.
This case report asks two questions: Does fuzzy wale elastic compression to control edema cause hemodialysis fistula to clot? Does fuzzy wales elastic textile improve healing when wound complications occur after access procedures?

Methods

One hemodialysis patient with a L arm surgical incision dehiscence directly above the gortex graft to brachial artery anastomosis. If the suture line below an open wound becomes infected and fails massive bleeding ensues. Negative Pressure Wound Therapy with foam + fuzzy wale elastic compression stockinet was used to control forearm edema.

Results

Photos document details of hemodialysis access wound complications, including vessels exposed, treatment details, and outcomes. Wound healed.

Conclusions

Fuzzy wale elastic compression therapy appears to be: (1) safe for the control of edema resulting from venous hypertension after dialysis arterial-venous fistula creation, and (2) effective to decrease edema, inflammation and cellulitis and to speed healing of the surgical incision.

References

1. Lunan MJ, McEntee M, Eisele G, et al. The emergency department care of hemodialysis patients. Clin. Nephrol. 2002;57:439-43.
2. Padberg, F. Complications of arteriovenous hemodialysis access: recognition and management. J Vasc Surg. 2008 Nov;48(5 Suppl):55S-60S.
3. Kozeny, D., Stott, K., "Longitudinal yarn compression textile: An innovative treatment for leg swelling." Journal of Vascular Nursing, Volume 25, Issue 3, Pages 62-62, September 2007

*EdemaWear® Compression Dynamics LLC Omaha Nebraska 68102.

Scott Wattenhofer, MD, FACS
Nebraska Methodist Hospital Dept of Vascular Surgery
University of Nebraska Department of Surgery (Contributed Service), Omaha, NE

Martin J. Winkler Sr., MD, FACS
Creighton University Department of Surgery (Contributed Service), Omaha, NE
University of Nebraska Department of Surgery (Contributed Service), Omaha, NE

University of Nebraska Medical Center
Alegent Creighton Health

*EdemaWear® Compression Dynamics LLC Omaha Nebraska 68102.