Hypochlorous Acid Improves Venous Leg Ulcer Healing:

Circulating epithelial cell precursor recruitment and control of biofilm bacteria appears to foster healing by enhancing epithelial daughter cell division

Problem

56 yo auto paint shop manager with

- Painful L recurrent VLU x 4 months
- 10 years post extensive skin split thickness grafting for bilateral nonhealing VLUs

Patient has negative memories of wound clinic therapy. Ten years ago he had painful venous leg ulcers that responded poorly to compression and required expensive split thickness skin grafting. He neglected painful sores on his leg for ~ 4 months before coming to wound clinic.

Treatment

- Topical Hypochlorous Acid (HOCl) at weekly clinic visits
- Weekly Soft Debridement of VLUs with HOCl pretreatment

Two VLUs 7 days after soft debridements with hypochlorous acid topical solution*, terry cloth and 7 days of fuzzy wale elastic compression therapy with a three layer "Omaha" dressing. Note that wound surface appears free of the exudate resulting from active biofilm bacteria.

Photo shows wound after one week of HOCL * local wound pretreatment, terry cloth scrubbing, and 3 layer dressing with fuzzy wale elastic compression. Flaking skin is evidence that dermatitis is healing rapidly. Shedding pathological layers of keratinized cells is evidence that compression is effective for reversing the pathophysiology of venous insufficiency. Typically, as in this patient, skin maceration leads to bacterial growth in skin at risk from stasis dermatitis. Macerated skin breaks down and ulcers result.

Shown here is the result of "soft debridement" at second wound clinic visit. Patient refused a second curette debridement. Soft debridement step one, soak the wound in HOCl solution 5 to 15 minutes soften the eschar. Step two, scrub, buff, the eschar with dry terry cloth. Note bleeding surface and eschar on the terry cloth. Patient tolerated required "buffing" at 3 visits until his VLU completely healed.
Topical HOCl therapy releases reactive oxygen that break bonds between individual amino acids in eschar proteins, a process similar to hypochloric acid (HCl) in gastric digestion of ingested protein, to effectively soften the scab. Think of HCl in the digestion of beef in the stomach. Presoaking the eschar with HOCl has been, in our hands, noticeably effective prior to "soft debridement". We believe HOCl acts as a mild local anesthetic by altering nociceptor pain ending function via contact with low PH. HOCl topical therapy has produce dramatic VLU healing at Omaha Mercy Wound clinic.

Wound area decreased 30% in 2 weeks - a remarkablty good result in a VLU present for ~4 months. Observe the robust epithelization that follows complete debridement and control of biofilm. Note decreased redness and edema in periwound skin marked with cornhusker furrows. Patient reports that pain is no longer a problem at week two.

In three weeks, small proximal VLU is declared "healed" by nursing staff. Observe dermatitis in at risk skin around the VLU has healed considerably.

Outcome

Complete VLU healing after five weeks of topical HOCl + fuzzy wale elastic compression

Conclusion

- Topical HOCl + elastic compression rapidly improved stasis dermatitis and healed VLU in 5 weeks. Clinic average is ~ 9 weeks for recurrent VLU with minimal comorbidities
- Topical HOCl controls of biofilm bacteria, which stimulates circulating epithelial precursor cell recruitment and daughter cell reproduction
- Fuzzy wale elastic compression drives edema fluid out of the wound bed which stimulates circulating epithelial precursor cell recruitment and daughter cell reproduction

Problem

- Recurrent VLU x 6 months
- Weeping Lymphorrhea with Congestive Heart Failure
- Noncompliant with CHF Rx
- Morbid Obesity
- Tracheotomy, pulmonary hypertension
- Sleeps sitting up to prevent apnea

At presentation the L lateral calf VLU was weeping lymph fluid, soaking patient's clothes and bedding. White arrow points to beads of clear lymph fluid weeping from cracks in the peri wound dermatitis.
Comorbidities: non-diabetic, chronic VLU (wound present > 12 weeks) weeping lymphorrhea from wound surface, noncompliant with CHF therapy, morbid obesity, tracheotomy, pulmonary hypertension due to obesity, sleeps sitting up to prevent apnea leading to leg edema (Pickwickian leg).

At presentation on July 31, 2012, the L lateral calf VLU was weeping lymph fluid, soaking patient's clothes and bedding. Weeping lymphorrhea is a serious comorbidity red flag that says — "expect a long siege, healing will be delayed". Weeping lymphorrhea is a critical comorbidity because wound surface lymphatic hypertension unhinges healing. We now believe that circulation epithelial cell precursors from the bone marrow are unable to reproduce in the face of an edematous lymphatic swamp. Accordingly we planned to step up to advanced wound healing modalities early.

White arrows show lymph fluid welling up in droplets on at risk skin after one week of fuzzy wale elastic compression. Note exuberant granulation tissue that reoccurred just one week after curette debridement. Lymphorrhea, in a surgical wound, is known to stimulate exuberant granulation tissue heavily colonized by bacteria. That process is seen in this wound.

Treatment

- Topical HOCl + debridement controls biofilm bacteria
- Elastic Compression

Pretreatment with topical hypochlorous acid* on a wash cloth is used to soften the eschar prior to "soft debridement" with dry terry cloth. Observe the fibrinoid exudate on the terry cloth. Note breakdown of macerated prebtial skin, the result of one week of honey alginate used inappropriately on a highly exudative wound.

Photo shows wound healing after ~12 weeks of elastic compression therapy, following a successful soft debridement with HOCl topical pretreatment.
Because of excessive lymphorrhea this exudative VLU was compressed initially with cotton batting based Robert Jones Dressings, changed twice a week, to absorb massive volumes of exudate. Subsequently profore type dressings, and then, more successfully, a two layer foam based compression dressing was used*** . In this patient with massive limb edema, recall he sleeps sitting up, after 12 weeks of elastic compression, the periwound at risk skin still has extensive dermatitis.

Outcome

Wound heals in 5 months

After four months of Robert Jones dressing changed twice a week and topical HOCl* the wound is healing. White arrows shows lymphorrhea fluid still welling up from the wound surface and at from at risk peri wound skin with stasis dermatitis.

Wound nearly healed after 5 months and 2 weeks. Bleeding follows curette debridement. Pink material on skin is a zinc oxide based skin protectant.

VLU declared "healed" at 5 months and three weeks. White arrows show that lymph fluid is still welling up from the wound. We doubt that this VLU could have healed, in the face of persistent lymphorrhea, without topical hypochlorous acid to control.

Conclusion

- Lymphorrhea unchecked over 6 months of wound therapy
- Topical HOCl heals wound

Topical hypochlorous acid* controls biofilm that plagues "wet" VLU wounds with lymphorrhea.

Problem

Hypochlorous acid (HOCl) is synthesized in white blood cells from hydrogen peroxide by the enzyme myeloperoxidase. HOCl is a small neutral molecule, easily diffuses into biofilms and across bacterial cell walls, oxidizing important bacterial organelles rapidly killing the bacteria.1 Fundamental pharmacology advances since the salt of HOCl, hypochlorite was first used for cleaning wounds on the battle fields of World War 1 have improved purity, efficacy, and shelf life of HOCl topical wound solutions.

At concentrations not toxic to cultured mouse lung epithelial cells HOCl* was the most rapidly bactericidal in vitro, compared to 19 current wound "cleansing preparations", achieving a 4 log kill of MRSA in less than one minute.2
We reported dramatic healing of venous leg ulcers (VLUs) with weekly topical HOCl therapy prior to mechanical wound debridement.3 Animal research shows that VLUs are healed by multiple generations of daughter cells derived from bone marrow epithelial precursor cells. Reactive oxygen species are an integral first step in signaling bone marrow to recruit circulating epithelial cell precursor migration to the wound bed.4 Control of biofilm bacteria enables rapid daughter cell division.5

Methods

Four patients with chronic and refractory VLUs were treated with topical HOCl* and fuzzy wale elastic compression**.

Results

All VLUs healed. Photos document details of treatment and healing.

Conclusions

Topical hypochlorous acid kills wound biofilm bacteria and appears to be highly salubrious for VLU healing. Reactive oxygen, from HOCl appears to be involved in recruiting epithelial precursors from the bone marrow and to foster effective daughter cell division in wound free of excessive biofilm bacteria.

References

1. Barker RM. "Oxygen-independent microbial killing by phagocytes (two parts)". N Engl J Med. 1978 Mar 23;298(12):659-68, N Engl J Med 1978; 298:721-725 March 30, 1978.
2. Rani S, Hoon R, Nagaft R, Khosravi B, Ph.D., Debdeep D. "The Antimicrobial activity of wound and skin cleansers at non-toxic concentrations". Manuscript in preparation
3. Robert Jones Dressing Changes Combined With Irrigation During Acoustic Powered Debridement Enhances Healing: HOCl irrigation is synergistic with acoustic powered debridement to decrease wound bioburden. Abstract Published; The Symposium on Advanced Wound Care, Anaheim, CA, September 2010. http://www.compressiondynamics.com/compress_links/Abstract_Hypochlorous_Acid_Irrigation_Enhances_Venous_Leg_Ulcer_Healing_2010.pdf
4. Thom SR, "The Physiology and Pathophysiology of the Hyperbaric and Diving Environments: Oxidative stress is fundamental to hyperbaric oxygen therapy". Journal of Applied Physiology, 2009;3, 988-995.
5. Liu2,J and Velazquez OC. "Hypersesia, Endothelial Progenitor Cell Mobilization, and Diabetic Wound Healing, Antioxidants & Redox Signaling". November 2008, 10(11): 1869-1882. doi:10.1089/ars.2008.2121.

* NeutroPhase®, NovaBay Pharmaceuticals, Inc., Emeryville, CA
** EdemaWear®, Compression Dynamics, LLC, Omaha, NE

*NeutroPhase®, NovaBay Pharmaceuticals, Inc., Emeryville, CA 94608
**EdemaWear®, Compression Dynamics, LLC, Omaha, NE 68102
*** CoFlex TLC (foam wrap roll), Andover Healthcare, Salisbury, MA 01952

Martin J. Winkler Sr., MD, FACS
Creighton University Department of Surgery (Contributed Service), Omaha, NE
University of Nebraska Department of Surgery (Contributed Service), Omaha, NE

Sandra Olson, BSN, CWON
Bergan Mercy Wound Care, Omaha, NE

Bergan Mercy Medical Center | University of Nebraska Medical Center | Alegent Creighton Health

Problem

- Traumatic R calf hematoma with necrosis of the overlying skin
- Anticoagulation for atrial fibrillation
- Hx nonhealing venous leg ulcers

Photo shows R calf hematoma injury 2 weeks after failing at his internist's office. Observe impressive circumferential painful swelling around a posterior calf hematoma, white arrow. This hematoma is "necessitating", that is working its way to the surface by causing pressure necrosis of the skin and subcutaneous fat. The tense hematoma measures 8 x 6 centimeter to palpation. It is a deep (below the fat), painful mass in the calf muscle and subcutaneous fat.
Scales and dermatitis at ankle, distended varicose veins, black arrow and "thin" transparent appearance of the skin is diagnostic of venous insufficiency.
Treatment: the #15 blade seen in the background was used to incise and drain the hematoma cavity in an effort to drain the old blood and minimize skin necrosis. A scant amount of old blood, seen in the gauze in the photo, drained from the hematoma. The cavity was irrigated with 250 ppm hypochlorous acid.* No antibiotics were given. Cotton batting was used in a bulky Robert Jones dressing to absorb hematoma drainage. Dressing change was scheduled for 3 days.

Treatment

- Incision and drainage of hematoma cavity
- Hematoma cavity irrigation with HOCl*
- Compression with fuzzy wale elastic compression 2 layer dressing

One week of treatment, after two Robert Jones dressing applications, clotted blood is draining from the I & D incision. Swelling and redness is decreasing dramatically. During HOCl irrigation, 7cc of blood was expressed from the hematoma cavity. Note that the swelling and red skin around the hematoma has disappeared. Pain is no longer a problem.

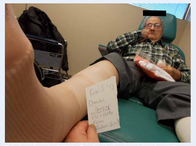

Patient seen here at visit #3, after 2 weeks of treatment, ready to go home with a two layer dressing. Calf skin is wrinkled as a result of wearing a well + fuzzy wale elastic compression stocking. Note the wrinkled skin in place with a new compression stocking.
Patient tested advances in B29 bombers while working the Enola Gay at Martin Bomber Works in Omaha. Comorbidities include Coumadin for atrial fibrillation, hx prior chronic nonhealing venous leg ulcers requiring 10 weeks of wound clinic care. Topical HOCl irrigation was used to control hematoma biofilm bacteria and no antibiotics were given the wound clinic. Intense pain abated after 2 days of compression with Robert Jones dressings.

Photo documents dramatic healing at clinic visit #3. Decreased pain, redness and edema with treatment over two weeks is dramatic.
Therapy to this point included: 1. hematoma evacuation and cavity irrigation with topical HOCl x 3; 2. one week of compression with cotton batting Jones dressings changed x2, and one week fuzzy wale elastic compression + foam.** Observe cornrow furrows in the skin, the result of fuzzy wale elastic compression stockinet. Activated charcoal cloth, seen in the foreground, was used as a sterile wound vell under the fuzzy wale compression stockinet. Patient was ambulatory and had extensive edema of toes and edema of skin above the stockinet cornrow furrows.

Prior to this photograph, a curette was used to evacuate old clot from cavity. Effective, comfortable hematoma cavity irrigation was a wrap with the finger pump. Irrigation fluaited out 3cc of clot.

Outcome

- Hematoma and overly necrotic skin "healed" in 3 weeks
- Clinic average for calf hematoma healing ~ 7 - 10 weeks

Conclusion

- HOCl irrigation of hematoma cavity evacuation speeds healing
- Elastic compression removes inflammatory mediators from the ectopic blood

Problem

Painful recurrent VLU x 5

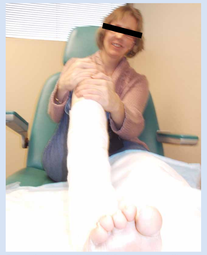

Frustrated 40 something year old with a painful R ankle venous leg ulcer, fifth reoccurrence. Patient works in retail and stopped wearing elastic compression during the Christmas sales season, 4 months after the prior VLU healed. The skin began breaking down 2 weeks after elastic compression was stopped. Pain was intense enough to make walking difficult. She presented to wound clinic on crutches.

Treatment

- Topical HOCl
- Fuzzy wale elastic compression + carbon cloth + collagen

Photo shows the VLU after topical HOCl therapy and debridement and one week of compression with standard three layer dressing. Observe the wrinkled skin and layers of damaged skin lifting off the VLU. Pain was exquisite because nociceptive pain nerves endings are intact and inflammation is intense. Patient was using crutches and oral narcotics.

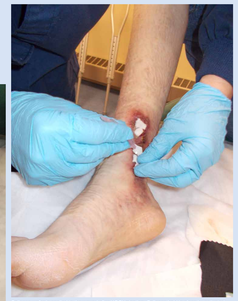

Collagen wafer is applied to the wound after HOCl irrigation. Collagen held in place by activated carbon cloth used directly on the granulating wound. Collagen acts as a substrate to neutralize harmful inflammatory mediators in the wound, e.g., collagenase and other matrix proteinase enzymes.
Because carbon cloth is thin, it allows the fuzzy wales to deliver effective compression directly to the healing surface. Additionally the thin layer of activated carbon (rayon cloth made into charcoal) inhibits biofilm bacteria and draws exudate away from the granulation tissue.
We surmise that topical Hypochlorous acid,* activated carbon cloth, fuzzy wale elastic compression** and collagen, act to improve local conditions: survival of circulating epithelial cell precursors that migrate from the bone marrow to the wound. Daughters of these epithelial daughter cells then close wounds.

Outcome

Recurrent VLU (x5) heals in 4 weeks

"Healed" VLU after 5 clinic visits with topical hypochlorous acid + fuzzy wale elastic compression + gelatin and cellulose.
Current research suggests that this therapy trio increases survival of circulating epithelial cell precursor daughter cells in wound granulation tissue. 1. HOCl kills biofilm bacteria; 2. fuzzy wale compression stockinet reverses venous stasis pathophysiology in the fat beneath skin; 3. gelatin acts as a substrate for matrix-metalloproteinases (MMPs) enzymes, collagenase to name one MMP, to decrease harmful wound bed inflammation.

Conclusion

- Topical HOCl kills bacteria that inhibit bone marrow precursor epithelial cells
- Topical HOCl controls wound biofilm bacteria painlessly

*NeutroPhase®, NovaBay Pharmaceuticals, Inc., Emeryville, CA 94608 **EdemaWear®, Compression Dynamics, LLC, Omaha, NE 68102 *** CoFlex TLC (foam wrap roll), Andover Healthcare, Salisbury, MA 01952