Four Layer VLU Compression Dressing Appears Safe for Profound Arterial Ischemia:

Moving Water from Subcutaneous Fat is Salutary for Skin Perfusion

Problem:

- Complete infrarenal aortic occlusion
- Partial post traumatic paraplegia, thus patient is not a candidate for extra anatomic bypass
- Exquisitely painful, on multiple narcotics
- NPWT failed due to maceration

This patient has a painful, profoundly ischemic R foot with no audible pedal doppler signals in, checked by author on three occasions. This vasculopath has an occluded aorta with an ABI of 0.0. Two board certified vascular surgeons recommended R BKA. Observe the maceration due to vinyl covering from unsuccessful negative pressure wound therapy. Observe three ischemic ulcers, exposed lateral malleolus capsule, edema of dependency and fibrin exudate. The ankle contracture deformity is the result of spinal chord injury and partial paraplegia.

Treatment:

- Fuzzy wale elastic compression to control swelling, layered dressing to control exudate*
- Hypochlorous acid** and ultrasonic debridement***
- Bioengineered skin substitute****

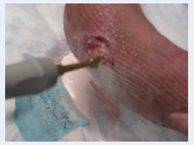

Ultrasonic powered debridement of forefoot wound. *** allows for humane control of extensive biofilm. Observe intense inflammation from ischemic dermatitis, pedal edema, and deep corrrow furrows from fuzzy wale elastic compression.*

Observe the deep corrrow furrows in the exuberant granulating wound surface. We consistently see improved granulation when the fuzzy wales sit directly on the granulating wound surface. The anecdotal observation that fuzzy wale compression stimulates granulation tissue, suggests that controlling edema on the wound surface with fuzzy wale compression is, like the control of wound surface edema with negative pressure wound therapy , NPWT, salutary for healing.

Observe healing five week after bioengineered skin.**** Observe that ischemic inflammation and edema has decreased with 5 weeks of fuzzy wale elastic compression.*

Corrrow furrows from fuzzy wale elastic compression are seen on the granulating wound. Patient launders her compression textile at home between weekly visits to the wound center. Fuzzy wale compression on the healing surface seems to speed healing by reepithelization. Reepithelization, we now believe, is due to daughter cell division from bone marrow derived circulating epithelial precursor cells that are recruited to the wound.

Outcome: Complete healing without scarring

Note corn now furrows in skin and complete healing without a scar. Healing without scar is said to be evidence that circulating epithelial cell precursors are at work. It is now understood that chemical signals from the living allograft cells stimulate the bone marrow to recruit circulating epithelial cell precursors. These circulating epithelial precursors colonize the wound. Multiple generations of daughter cells spread over the surface and close the wound with minimal scarring.

Observe the deep corrrow furrows that result from edema fluid moving out of the wound bed. Fuzzy wale elastic compression stockinet* has effectively treated the previously inflamed swollen dermatitis. We believe that fuzzy wale elastic compression improved the survival of circulating epithelial precursor daughter cells in this patient.

Problem:

- Nonhealing exquisitely painful venous leg ulcers
- Nonagenarian Air Corp veteran served in occupied Japan
- Painful stasis dermatitis
- Comorbid COPD on prednisone, CHF on digoxin and diuretics
- Arterial occlusive disease, ABI 0.25/0.35

Edematous red skin is the result of venous stasis dermatitis. Pain prevented adequate debridement at a university wound care center. These ulcers were treated on and off for four months with collagenase ointment. Ankle brachial index was 0.25/ 0.35, R/L , performed in the wound center. Comorbidities included: Atherosclerotic peripheral vascular disease, VLU present > 6 months, oral prednisone and nasal oxygen for COPD, CHF with edema of the limbs requiring diuretics.

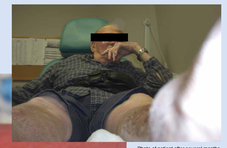

Photo of patient after several months of fuzzy wale elastic compression therapy. Photo shows corrrow furrows in the skin that is no longer red, swollen, and painful. Where once there was painful, swollen, at-risk skin, bright red with dermatitis, now there is healing. Unfortunately the venous leg ulcers are still present. Four weeks of wound center therapy passed with a no improvement in the size of the VLUs, suggesting that "advanced wound therapy "was required.

Treatment:

- Fuzzy wale elastic compression* starts at week #4
- Two application of bioengineered human skin substitute****
- Ultrasonic powered debridement,*** Hypochlorous acid irrigation (HOCl)**

This patient illustrates several lessons on treating VLUs, venous leg ulcers, with fuzzy wale elastic compression. Sharp debridement at the first visit, as shown in photo above, was limited by pain. Adequate elastic compression was limited by painful dermatitis. At the first visit, to deliver compression to the painful skin, a Robert Jones dressing, with fuzzy cotton batting against the dermatitis, ACE wrap and Coban dressing was applied.

After four weeks of Robert Jones dressing, swelling and pain decreased to the point that standard fuzzy wale elastic compression* could be started. As a result of this patient, and other patients presenting with painful VLUs that standard elastic compression was not possible. In response to our experience with this WWII veteran of the Pacific theatre, we developed a fuzzy wale "LITE" elastic stockinet* that delivers less compression and is comfortable for inflamed painful skin such as seen in the photo above.

Photo shows the venous leg ulcers (VLUs) being "grafted" with bioengineered skin substitute, a homograft of bi-layered epithelial cells derived from infant foreskin. A one millimeter skin biopsy punch was used to fenestrate the living cell allograft graft, note the crescent shaped incisions in the cultured skin. These bioengineered tissue cultured epithelial cells will survive ~ 2 weeks on this wound. While they are alive these allograft cells send strong messages to the bone marrow to recruit circulating epithelial precursor cells to the wound bed. Current research suggests that is the daughter cells of circulating epithelial precursors act to close the wide flat VLU wounds. The transient residence of allograft cells is highly effective for recruiting epithelial circulating precursor cells to the granulating wound.

Anecdotal case studies suggest that fuzzy wale longitudinal compression textile creates a highly effective wound milieu intérieur that is salutary for the incubation of multiple generations of daughter cells required for epithelial cell coverage of the wound bed.

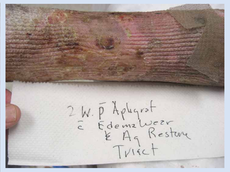

Complete VLU healing required a second application of bioengineered human skin, 10 weeks after the first bioengineered skin graft.****. Cultured epithelial cells from human infant foreskin send powerful signals to the bone marrow—mobilize epithelial precursor cells to close the wound. These living bioengineered epithelial cells do not survive much beyond two weeks on the wound surface.

Outcome:

- Inflammation from stasis dermatitis disappears after ~ 4 months with fuzzy wale elastic compression*
- Complete healing of the VLUs at ~11 months
- Two applications of bioengineered skin substitute****

Complete resolution of the stasis dermatitis and complete VLU healing. Healing was complicated in this patient with arterial occlusive disease, ankle brachial index ABI 0.25.

Problem:

- Post MI ICU "TED sore"
- R Heel and calf necrosis following MI with low cardiac output & stupor
- R superficial femoral artery occlusive disease, ABI 0.31

Observe necrotic heel, inflammation and massive edema five weeks after discharge from the ICU. Heel pressure sores are rare in the absence of arterial occlusive disease. This 84 y.o. nonsmoking, nondiabetic had ABI of 0.30.

These necrotic lesions resulted from low perfusion and "pressure" on the heel while covered by TED hose in a university ICU in the five days following a MI with stupor. TED hose are not effective to prevent pulmonary embolus. TED hose can, as in this patient, be harmful, by obscuring the clinical findings that establish the status of the skin perfusion.

Treatment:

- Full thickness eschar debridement in clinic
- Angiogram with percutaneous R femoral atheroectomy***** in response to delayed healing

Wound is stalled after 7 weeks of treatment. Vascular surgery and cardiology consults came back with "low cardiac ejection fraction, <18%, makes this patient unfit for vascular intervention (normal EF > 60%)." Consultation with cardiology lead to a low impact alternative plan: cardiology service would perform a low impact R limb angiogram and perform a percutaneous powered catheter atheroctomy to the R femoral and popliteal artery..

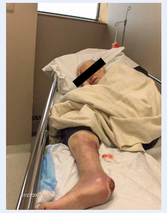

Wounds are healing – 10 weeks after atherectomy by cardiology service.****

Limb still appears edematous after months of layered dressing. Wounds appear ready for a split thickness skin graft. Importantly, in 2007 we were NOT yet using Fuzzy wale elastic compression stockinet on profoundly ischemic limbs. The decision for STSG required a cardiology consult to clear patient for local anesthesia.

Outcome:

- Fuzzy wale compression speeds maturation of skin graft, STSG
- Fuzzy wale compression toughens up STSG and prevents heel graft from recurrent breakdown

First split thickness skin graft dressing change 03/06/2007 shows complete take of the STSG. Observe extensive limb edema.

During the treatment of these wound, edema from CHF remained a constant comorbid problem for this patient. After the skin graft second dressing change, we tried fuzzy wale elastic compression for calf edema control. In spite of our initial fears fear that poor perfusion might result from fuzzy wale elastic stockinet, results on the calf and heil were dramatic, as seen above. In one week of fuzzy wale elastic compression, the calf STSG (as seen above) dramatically "toughened up".

Photo shows breakdown of STSG on heel and extensive edema ~10 weeks after skin surgery in spite of padded dressing and Rooke boot. Because fuzzy wale compression helped toughen the calf skin graft, the decision to use fuzzy wale elastic compression* directly on the heel was made. After this patient experience, we began using fuzzy wale compression to control edema in all ischemic limbs with ulceration and ischemic dermatitis with consistently good results.

Problem:

Institutionalized profoundly retarded 58 y.o. male

- L lateral malleolus ulcer
- Arterial occlusive disease ABI 0.35
- Nondiagnosed vasospasm, cold acrocyanotic pedal skin mottling

Initial therapy at institution was a faux sheepskin Rookie Boot, stoma adhesive to protect the L lateral malleolous from trauma and fuzzy wales elastic compression to control dependent edema.

Note gastrostomy feeding tube at left hip, muscle wasting, truncal obesity, and bright red lips, consistent with chronic poor nutritional state. Patient was on high dose antipsychotic medications which are known to cause alpha adrenergic vaso compression of the skin. Antipsychotic drugs may have contributed to the mottled cold skin changes we see in this patient..

Observe skin mottling and chronic toenail changes consistent with arterial occlusive disease. Ankle brachial index, L leg is 0.3. High dose antipsychotic medications are known to cause alpha adrenergic vaso compression of the skin. Antipsychotic medication may have contributed to the mottled cold skin changes we see in this patient. After one week of fuzzy wale elastic compression, note corrrow furrows in the skin, the mottling is less.

Treatment :

- Negative pressure wound therapy (NPWT)
- Fuzzy wale elastic compression stockinet*

Observe dramatic improvement, after ~8 weeks of elastic compression, and bilateral faux shearling sheep skin in appearance of the skin. Skin mottling and edema have decreased. NPWT device is held in place by fuzzy wale elastic compression textile. The outcome of this 2007 case opened our eyes to the possibility that fuzzy wale elastic compression was not only safe, but helpful, salutatory for profoundly ischemic skin.

Outcome:

- Lateral malleolus ulcer heals in ~11 wks
- NPWT x 4 weeks
- Fuzzy wale elastic compression & Rooke boot

In this photo NPWT has been discontinued. Observe the skin, after weeks of fuzzy wale compression, is no longer mottled corrrow furrows are directly on the healing wound surface. Several weeks later the eschar fell off the healed wound. Importantly in terms of cost, no angiogram was ordered and no inpatient care was required. This patient's good outcome with fuzzy wale elastic compression, early on, encouraged us to use fuzzy wale compression on other patients with ischemic limbs. We now believe that fuzzy wale elastic compression stockinet is therapeutic for ischemic skin.

Purpose:

Moffatt, at Charring Cross London, introduced four layer dressings for venous leg ulcers that have been widely embraced around the world.(1, 2, 3) After extensive use, initial concerns about arterial necrosis due to excessive concentric compression layers have not been realized. Initial Doppler pressure, ABI, guidelines, set up to protect from ischemic complication, stalled "... compression is not usually recommended with an APBI of lower than 0.8,' are not well supported by clinical data.(4,5) Kozeny introduced focused fuzzy wale elastic compression (FWC) stockinet in 2007 that limits compression to 20% of the skin surface and rapidly moves water out of subcutaneous fat.(6) No Doppler blood pressure guidelines were advocated. This case series and extensive clinical use suggests that FWC is not only safe, but may be therapeutic for at-risk ischemic skin.

Methods:

FWC was used as the elastic engine of a four layer dressing to treat four chronic VLUs with comorbid profound arterial ischemia.

Results:

Photos document technical details of therapy and the healing of all wounds.

Conclusion:

Fuzzy wale elastic compression, FWC, appears safe for the elastic compression of VLUs with co-morbid arterial occlusive disease. The observation of healing in spite of low ABI values raises the possibility that focusing fuzzy wale compression on 20% of the skin surface improves arterial perfusion of at risk skin..

References:

1. Moffatt, Christine; Four-layer bandaging: from concept to practice Part 1: Application of the four-layer system, http://www.worldwidewounds.com/2004/december/Moffatt/ Developing-Four-Layer-Bandaging.html#summary
2. Moffatt, Christine; Four-layer bandaging: from concept to practice Part 2: Application of the four-layer system, http://www.worldwidewounds.com/2003/september/Thomas/New-Compression-Bandage.html
3. Franks PJ, Moffatt CJ, Connolly M, Bosanquet N, Oldroyd MI, Greenhalgh RM, et al. Factors associated with healing leg ulceration with high compression. Age Ageing 1995; 24(5): 407-10.
4. RCN Institute, Centre for Evidence-Based Nursing, University of York, School of Nursing, Midwifery and Health Visiting, University of Manchester. Clinical practice guidelines: the management of patients with venous leg ulcers. London: RCN Institute, 1998.
5. Marston W, Vowden K. Compression therapy: a guide to safe practice. In: Understanding compression therapy: EWMA Position document . London: MEP Ltd, 2003; 11-17.
6. Kozeny D, Stott K. Longitudinal yarn compression textile: An innovative treatment for leg swelling. Journal of Vascular Nursing Volume 25, Issue 3 , Page 62, September 2007.

Product Suppliers:

* EdemaWear®, EdemaWear LITE™, Compression Dynamics LLC, Omaha, NE; Stayfoxx™, Aracapa Technologies Inc., San Dimas, CA

** Vashe®, PuriCore, Malvern, PA

*** SonicOne®, Misonix Inc., Farmingdale, NY

**** Apligraf®, Organogenesis Inc., Canton, MA

***** SilverHawk™ Plaque Excision System with Proprietary MEC Technology, Covidien, Plymouth, MN

Martin J. Winkler Sr. MD FACS
Creighton University
University of Nebraska College of Medicine
Omaha, Nebraska

Alan S. Neil BSc.
ASN Associates
Indian Shores, Florida

Sara Monica Winkler
Stanford University,
Palo Alto, California

University of Nebraska Medical Center

Alegent Health

Creighton University Medical Center